

January 2018

Cribado de la retinopatía diabética en el primer nivel de atención usando retinografía en la Ciudad de México

Daniel Paniagua Herrera

Universidad Autónoma de México, danielpaniagua23@gmail.com

Consuelo González Salinas

Universidad Autónoma de México, danielpaniagua23@gmail.com

Follow this and additional works at: <https://ciencia.lasalle.edu.co/svo>



Part of the [Eye Diseases Commons](#), [Optometry Commons](#), [Other Analytical, Diagnostic and Therapeutic Techniques and Equipment Commons](#), and the [Vision Science Commons](#)

Citación recomendada

Paniagua Herrera D y González Salinas C. Cribado de la retinopatía diabética en el primer nivel de atención usando retinografía en la Ciudad de México. *Cienc Tecnol Salud Vis Ocul.* 2018;(2): 11-19. doi: <https://doi.org/10.19052/sv.5068>

This Artículo de Investigación is brought to you for free and open access by the Revistas científicas at Ciencia Unisalle. It has been accepted for inclusion in *Ciencia y Tecnología para la Salud Visual y Ocular* by an authorized editor of Ciencia Unisalle. For more information, please contact ciencia@lasalle.edu.co.

Artículos de investigación científica y tecnológica

Screening of Diabetic Retinopathy in Primary Care by Retinography in Mexico City

Cribado de la retinopatía diabética en el primer nivel de atención usando retinografía en la Ciudad de México

DANIEL PANIAGUA HERRERA 
CONSUELO GONZÁLEZ SALINAS ^{**}

Received: 10-10-2017 / Accepted: 02-20-2018

ABSTRACT

Objective: To determine the prevalence of diabetic retinopathy and diabetic macular edema by means of retinography in patients diagnosed with Type 2 diabetes mellitus according to time of evolution and degree of vision loss with and without refractive correction. *Method:* A descriptive cross-sectional study of 150 patients with Type 2 diabetes mellitus assessed in optometry in various health centers from the Sanitary Jurisdiction of Tlalpan, Health Services of Mexico City. *Results:* 150 patients (70% women, 30% men) aged 60 (+/- 7.77) were diagnosed with Type 2 diabetes mellitus, 52% of them with an evolution of 12.09 years (+/- 3.48). Of the total number of patients, 72.33% had retinopathy and/or diabetic macular edema lesions. The average visual acuity improved from 0.62 (+/- 0.48) to 0.37 (+/- 0.38) with refractive correction, absolute disability decreased by -18.76% and null or slight disability increased by 31.31%. Of the total population, 75.5% remained under monitoring in primary care, and 24.5% were referred to tertiary care in ophthalmology. *Conclusion:* The strategic opportunity to combat vision loss due to retinopathy and diabetic macular edema is found in its timely detection by health personnel trained in scrutiny and control at the primary care level, which would represent a decreased hospital load in tertiary care, thereby reducing costs for the health systems, as well as cost-efficiency for the years of sight gained and optimization of the patient's global vision.

Keywords: Diabetic retinopathy; diabetic macular edema; visual capacity.

* Licenciado en Optometría, Universidad Autónoma de México.  danielpaniagua2003@gmail.com

** Médico, Universidad Autónoma de México. Especialista en Medicina Familiar.

Cómo citar este artículo: Paniagua Herrera D, González Salinas C. Screening of diabetic retinopathy in primary care by retinography in Mexico City. *Cienc Tecnol Salud Vis Ocul.* 2018;16(2):11-19. doi: <https://doi.org/10.19052/sv.5068>

RESUMEN

Objetivo: Determinar la prevalencia de retinopatía diabética y edema macular diabético mediante retinografía en pacientes diagnosticados con diabetes mellitus tipo 2 según el tiempo de evolución y el grado de pérdida de visión con corrección refractiva sin esta. **Método:** Estudio descriptivo de corte transversal de 150 pacientes con diabetes mellitus tipo 2 evaluados en optometría, provenientes de diversos centros de salud pertenecientes a la Jurisdicción Sanitaria de Tlalpan, Servicios de Salud de la Ciudad de México. **Resultados:** 150 pacientes (70% mujeres, 30% hombres) de 60 años ($\pm 7,77$) fueron diagnosticados con diabetes mellitus tipo 2 (52%) con una evolución de 12,09 años ($\pm 3,48$). El 72,33% tiene retinopatía y/o lesiones de edema macular diabético. La agudeza visual promedio mejoró de 0,62 ($\pm 0,48$) a 0,37 ($\pm 0,38$) con corrección refractiva; la discapacidad absoluta disminuyó en -18,76% y la discapacidad nula o leve aumentó en 31,31%. **Conclusión:** Existe una oportunidad estratégica para combatir la pérdida de visión debido a retinopatía y edema macular diabético en la detección oportuna por parte del personal de salud capacitado en examinación y control estratégicamente ubicado en el primer nivel de atención; esto representaría una reducción de la carga hospitalaria del tercer nivel, reduciendo así los costos para los sistemas de salud, lo cual significaría rentabilidad por los años de visión ganados y optimizaría la visión global del paciente.

Palabras clave: retinopatía diabética, edema macular diabético, capacidad visual.

INTRODUCTION

Diabetes mellitus (DM) is a worldwide public health problem; in fact, it is estimated that, in 2015, 415 million people were suffering from diabetes, and that by 2040 that number will increase to 642 million, according to the International Diabetes Federation (IDF) (1). According to the National Health and Nutrition Survey, the prevalence of diabetes in Mexico increased from 9.2% in 2012 to 9.4% in 2016, based on a previous diagnosis of the disease (2). However, the actual number of people suffering from DM is expected to be twice as high, considering that many individuals are unaware of their condition.

The IDF describes three main types of DM (1):

- 1) *Type 1 or insulin-dependent diabetes.* It is caused by an autoimmune reaction that compromises the beta cells of the pancreas, leading to a deficient production of insulin and thus requiring a daily application of this hormone. It affects people at any age but it is more common in children and young adults.
- 2) *Diabetes type 2 (DM2), non-insulin dependent.* The result of the ineffective action of insulin, it is the most common type of diabetes world-

wide, caused mainly by being overweight and having a sedentary lifestyle. The symptoms may be detected after the disease has progressed for several years and the first complications manifest. DM2 used to manifest only in adults, but nowadays it also manifests in children.

- 3) *Gestational diabetes.* It is characterized by hyperglycemia during pregnancy and may end after birth, increasing the risk factor for developing DM in a period of 5 to 10 years.

Other specific types of DM develop due to alterations of the pancreas, associated with endocrine diseases, genetic defects in the function of beta cells, and genetic defects in the action of insulin. Thus, diabetic retinopathy (DR) is the result of microvascular alterations closely associated with the type and time of evolution of DM, blood glucose (chronic hyperglycemia), blood pressure and probably lipids, although the mechanism by which hyperglycemia causes microvascular damage in the retina is unknown (3,4).

Diabetic retinopathy and diabetic macular edema (DME) are secondary complications to DM, being one of the main causes of irreversible vision loss. Literature lists different criteria for the classification of DR, some of which are so complex that

they are used for research purposes. The Early Diabetic Retinopathy Study (ETDRS) has been consolidated as the “gold standard” that makes it possible to know about the development of the disease, the risk factors, and the treatment based on the degree of severity. Diabetic retinopathy was classified as: without diabetic retinopathy (without alterations), mild non-proliferative diabetic retinopathy (NPDR) (micro aneurysms), moderate NPDR (more than just micro aneurysms, but less severe NPDR), severe NPDR (any of the following: more than 20 intraretinal hemorrhages in the four quadrants, venous embrittlement in two or more quadrants, or intraretinal microvascular anomalies in one or more quadrants), and proliferative diabetic retinopathy (PDR) (neovascularization or preretinal or vitreous hemorrhage). On the other hand, diabetic macular edema was classified, as: without DME (DME absent) and clinically significant DME (retinal thickening and/or hard exudates at 500 microns or less to the macula) (5,6).

In Scotland, the DR screening program was developed based on retinographies, a safe test that can be performed without having to dilate the pupil in most cases, which offers high sensitivity and specificity for threats to vision resulting from diseases. The program provides easy access, storage and transmission of images, which can be consulted by one or several people in order to guarantee assertiveness in the diagnosis, and it is also cost-effective. The retinography, assessed by certified personnel for scrutiny, contributes to the management, control, follow-up or referral to tertiary care ophthalmology, depending on the degree of severity. The Scottish classification system of DR (7,8) is a simplified and clinically relevant form for DR screening (Table 1).

Loss of vision by DR and/or DME is the result of injuries caused by DM and/or DME, with other associated causes, such as refractive error, cataract, and glaucoma, among others. The Wecker's scale (9) is a legal criterion used in Spain to determine the overall visual disability of the individual, considering the visual acuity (VA) of the best and worst

eye, establishing percentages of visual decrease and thus determining their degree of visual loss (Table 2).

TABLE 1. Classification of diabetic retinopathy and diabetic macular edema according to Scottish criteria (7,8)

DIABETIC RETINOPATHY	
R0	Absence of diabetic retinopathy
R1	Hemorrhages, micro aneurysm, hard exudates, cottony exudates
R2	Four or more spot hemorrhages in a hemifield
R3	Four or more spot hemorrhages in a hemifield, venous rosary, intraretinal vascular abnormalities
R4	Vitreous hemorrhage, preretinal hemorrhage, neovessels, laser traces
R6	Not valuable
DIABETIC MACULAR EDEMA	
M0	Absence of injuries within 2 disc diameters (DD) of the fovea
M1	Hard exudates and/or injuries > 1 DD and < 2DD
M2	Lesions in < 1DD of the center of the fovea
M6	Not valuable

TABLE 2. Classification criteria for global vision loss according to Wecker's scale (9): Materials and methods

Degree of disability	Percentage of global visual loss
Null or mild disability	0–23
Partial disability	24–36
Total disability	37–50
Absolute disability	> 50

A transversal descriptive statistical analysis was carried out between January 2016 and August 2017, in which 150 patients were evaluated (70% women and 30% men), diagnosed with DM2 and referred from family medicine to optometry, which is part of different Health Centers of the Sanitary Jurisdiction of Tlalpan, Mexico City.

A questionnaire was applied to patients under express verbal consent to obtain demographic data and systemic pathologies. Patients who denied the medical diagnosis of DM2 and those who did not know its time of the evolution were selected. Monocular VA tests were performed with Snell Primer (literate and illiterate) at a distance of 3 meters with photopic illumination, static retinoscopy tests with a test box and framework for obtaining corrected VA images and eye fundus exploration with non-mydriatic eye camera in retinographies

with artifacts and refractive devices by indirect ophthalmoscope and fundus examination system for mobile devices for documentation of injuries (Figure 1).



FIGURE 1. 36-year-old female patient diagnosed with DM2 with 25 years of evolution. Left eye: VA 20/25 hemorrhage in spot. Scottish classification R1, M1. Referral to tertiary care

Source: Retinography database of the Medical Specialty Units of Chronic Diseases (UNEME cc) at Tlalpan.

The criterion according to the Scottish classification of RD (7,8) (Table 1) was used for weighing of the degree, and the degree of visual incapacity was determined based on Wecker's scale (Table 2) with and without refractive correction.

RESULTS

In the study, 150 patients from primary care centers from the Sanitary Jurisdiction of Tlalpan of the Government of Mexico City were seen. The patients were both female (70.0%) and male (30.0%), 97.99% with an average age of 60 years (+/- 7.77), after a medical diagnosis of DM2 (58.0%) and in comorbidity with Systemic Arterial Hypertension (HAS) (52.0%), with an average time of evolution of DM2 of 12.09 years (+/- 3.48).

Out of 150 patients diagnosed with DM2 and treated at primary care centers from the Sanitary Jurisdiction of Tlalpan of the Government of Mexico City, 108.5 (72.33%) were found to have DR and/or DME. According to the Scottish classification of DR and DME, an increase in severity is observed in the age range (Table 3) according to the time of evolution of diabetes.

TABLE 3. Distribution of findings of retinopathy and diabetic macular edema, classified according to the Scottish criterion by time of evolution of Type 2 Diabetes Mellitus (n = 300 eyes)

DIABETES EVOLUTION TIME	DIABETIC RETINOPATHY						DIABETIC MACULAR EDEMA			
	R0	R1	R2	R3	R4	R6	M0	M1	M2	M6
≤ 5 years	63	1	0	0	0	2	64	0	0	2
6 to 10 years	72	8	5	0	0	7	76	1	6	9
11 to 15 years	21	19	6	2	3	11	30	6	14	12
16 to 20 years	17	7	8	3	3	2	20	3	13	4
21 to 25 years	3	2	2	4	2	7	4	4	5	7
≥ 26 years	4	10	2	0	4	0	9	5	6	0

Source: CS THH database, Dr. Castro Villagrana.

The descriptive statistical analysis of the prevalence at intervals of 5 years of diabetes evolution showed an increased percentage of both DR and DME in patients (Figure 2).

The loss of vision according to weighting with Wecker's scale (Figure 3) determined that absolute disability is improvable, decreasing from 29.45% to 10.69% with refractive correction, showing a decrease of 18.76%; total disability improved from 15.75% to 9.92%, showing a decrease of 5.83%; partial disability improved from 28.08% to 21.37%, showing a decrease of 6.37%; and null or mild disability increased by 31.31%, going from 26.71% to 58.02.

Visual acuity in the Average MAR Log improved from 0.62 (+/- 0.48) to 0.37 (+/- 0.38) with refractive correction, reducing absolute disability by -18.76% and increasing null or slight disability by + 31.31%.

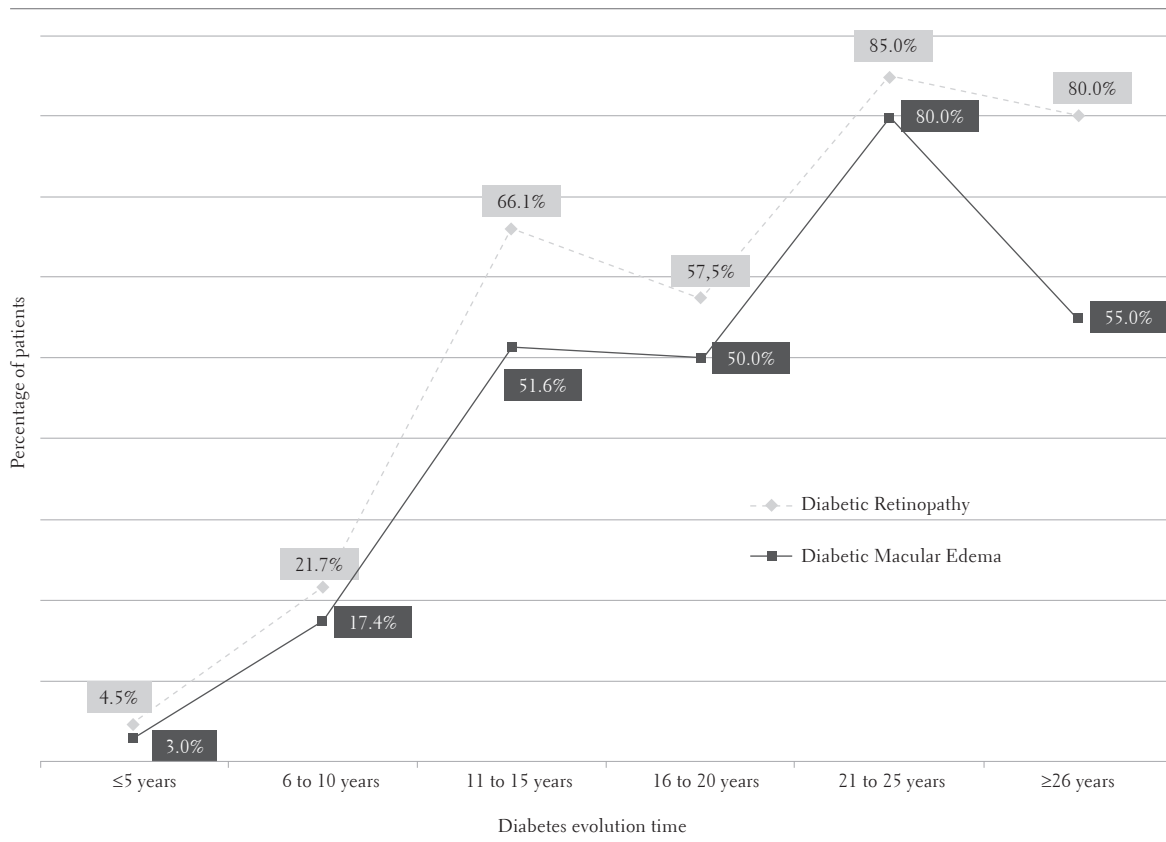


FIGURE 2. Increase in percentage of diabetic retinopathy and diabetic macular edema by time of evolution of diabetes

Source: CS TIII database, Dr. Castro Villagrana.

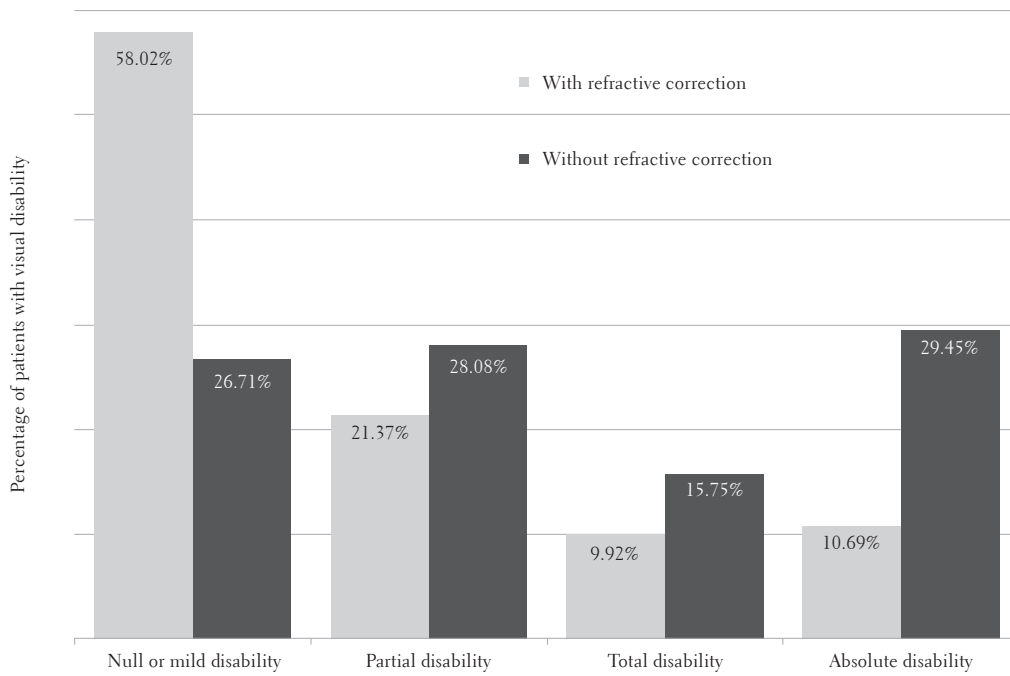


FIGURE 3. Distribution of visual disability in two groups, with and without refractive correction, based on Wecker's scale criterion

Source: CS TIII database, Dr. Castro Villagrana.

The referral to tertiary care in ophthalmology (Figure 4) reflects a higher percentage of patients under control in primary care (75.5%) versus referrals to tertiary care in ophthalmology (24.5%) based on the Scottish RD Screening Criterion.

DISCUSSION

The early detection of DR is the responsibility of the patient and of the relatives, caregivers and health personnel who are in direct contact with the patient, emphasizing the relevance of the annual visual examination, which allows detecting injuries that compromise the patient's vision in a timely manner. It is also worth noting that DR can be asymptomatic, meaning that the patient has acceptable eyesight without any symptoms of the disease, and that the continuity of the vision is favored by a timely medical attention, which would be less expensive and more effective.

The time of evolution of DM2 is a characteristic that influences the increase in the percentage

of DR and/or DME (10,11). Previous studies of prevalence of DR carried out in Mexico found a prevalence of DR of 33.3% in the state of Hidalgo with an evolution of 9.9 years (12), of 71% in Guanajuato with an evolution of up to 12 years (13); in Durango, the prevalence of DR was of 21.3% in patients with an evolution of less than 5 years, and of 80.7% in patients with an evolution of 15 years or more (14). The General Hospital of Mexico reports a greater prevalence of DR in patients with 15 years or more of evolution (15), and in the present study the prevalence was of 21.7% in patients with evolution of 10 year, of 66.1% in patients with evolution of 15 years, and of 85.0% in patients with evolution of 25 years or more. The population of the studies carried out in different Mexican states is heterogeneous in terms of ethnic groups, age, and sex, and the prevalence of DR tends to increase (Figure 5).

The implementation of screening strategies in patients with DM in primary care would represent an effective model (16-18), with elements such

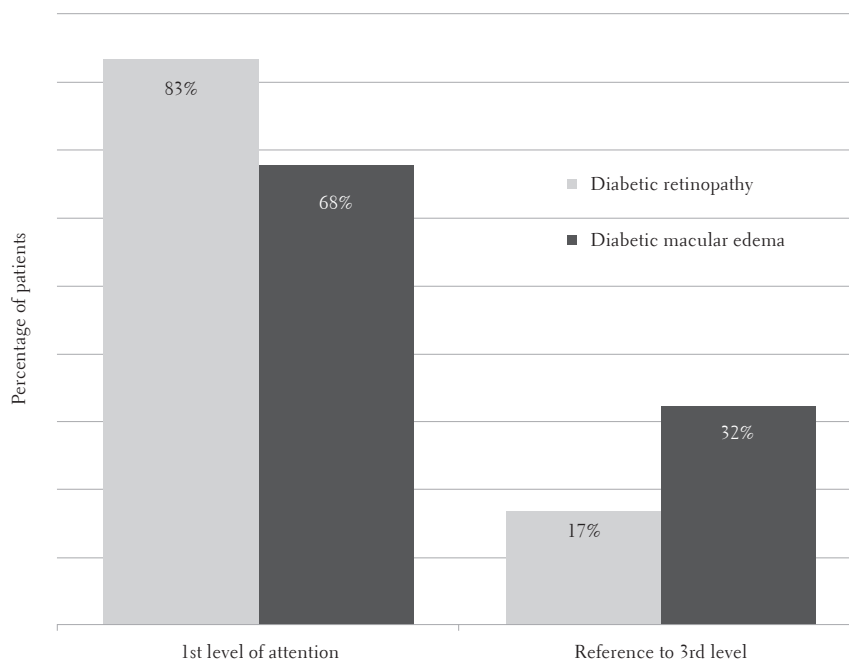


FIGURE 4. Percentages of patients suffering from DM2 in follow-up control with Retinography by RD and/or DME in primary care and referral to tertiary care in ophthalmology according to Scottish Criteria (n = 150 patients)

Source: CS THH database, Dr. Castro Villagrana.

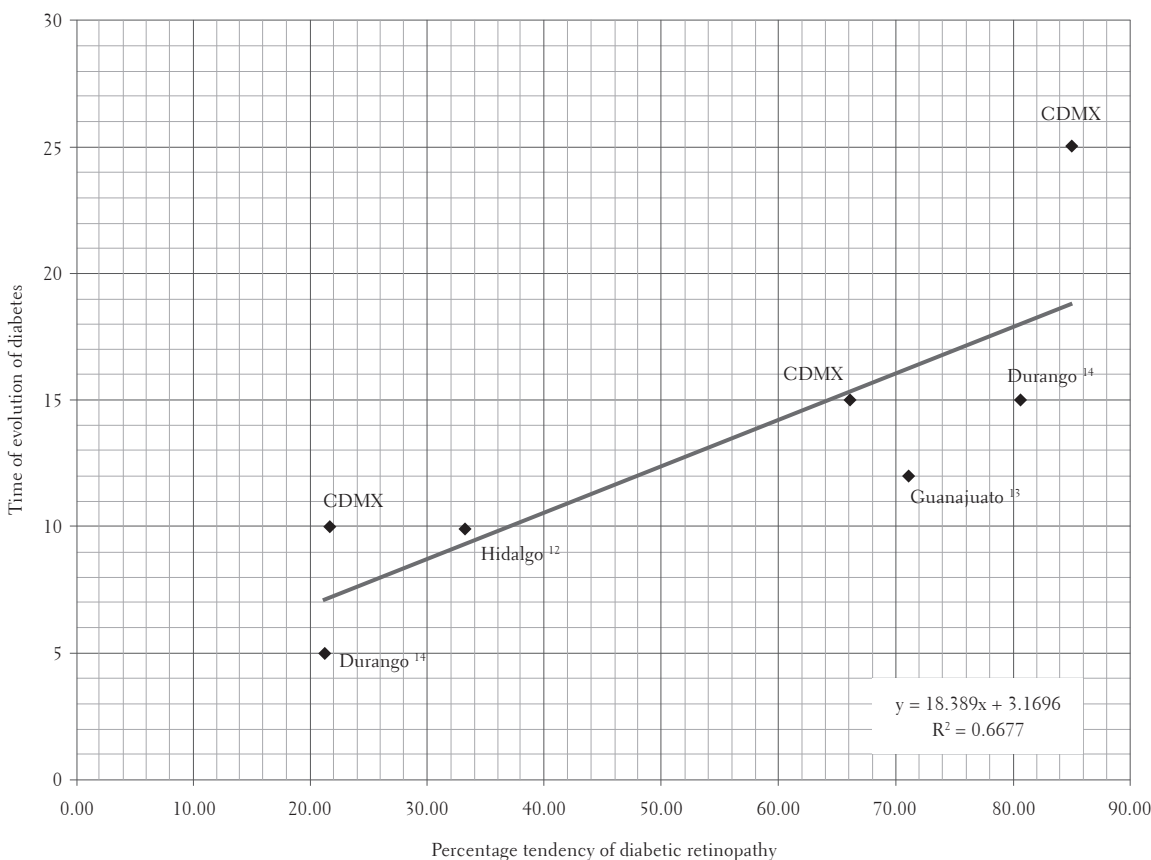


FIGURE 5. Percentage tendency of diabetic retinopathy due to time of evolution of diabetes in the Mexican population (12–14)

as medical history, visual examination, taking appropriate quality retinographies, focusing on patients without screening before or after being diagnosed with DM2, implementing a periodic review plan according to their stage or referral to ophthalmology for a more thorough follow-up and/or treatment of injuries.

DR and/or DME leads to irreversible loss of vision (19), and refractive correction contributes to decreasing visual disability despite injuries. Part of the optometric model in care and rehabilitation of patients with DM is refractive correction, which increased null or slight disability by +31.31% and reduced absolute disability by –18.76%, thus contributing to the patient's being able to resume domestic, trade, and recreational activities etc. It also reduced the impact of depression and anxiety caused by visual disability (20). Consideration for

refractive correction may be subject to the degree of visual impairment of the patient.

Referral to tertiary care in ophthalmology for DR represents a greater cost when there is no effective DR screening model in primary care (21). Optometrists must have the clinical sensitivity to implement DR (22) screening, and so training and certification should be the basic norm for DR screening. Opportunistic screening would be cost-effective for the years of vision loss saved.

CONCLUSIONS

Screening of DR by retinography in primary care by trained optometrists aimed at DM2 patients (n = 150) found that 72.33% of the patients suffered from DR and/or DME. Refractive correction favored null or mild disability by +31.31% and

reduced absolute disability by -18.76% ; moreover, average visual acuity, measured with the LogMar chart, improved from 0.62 (± 0.48) to 0.37 (± 0.38) with refractive correction. Of the total number of patients, 24.5% were referred to tertiary care in ophthalmology and 75.5% were seen and monitored in primary care.

ACKNOWLEDGEMENTS

We would like to thank Dr. Arelly Leyva Castrejón, Dr. Fernando Rey Monroy Ramírez and Dr. Maribel López Alquicira for their support in providing us with the resources for obtaining data for the study. We would also like to thank Dr. David Rivera de la Parra, and Dr. Aida Jiménez Corona for their contribution in training to consolidate a clinical value criterion. Finally, special thanks to Dr. Silvia Elsa Varela Arébalo† for her firm belief in optometry and for making the difference for the benefit of patients.

REFERENCES

1. Federación Internacional de Diabetes. Atlas de la diabetes del FID. 7th ed. 2015. Available from: <http://www.fundaciondiabetes.org/general/material/95/avance-nuevo-atlas-de-la-diabetes-de-la-fid-7-edicion-actualizacion-de-2015>
2. Instituto Nacional de Salud Pública. Encuesta Nacional de Salud y Nutrición de Medio Camino 2016: informe final de resultados. México: Instituto Nacional de Salud Pública; 2016. Available from: http://oiment.uanl.mx/wpcontent/uploads/2016/12/ensanut_mc_2016-310oct.pdf
3. Aguilar Salinas CA, Hernández Jiménez S, Hernández Ávila M, Hernández Ávila JE. Acciones para enfrentar a la diabetes. México: Consejo Nacional de Ciencia y Tecnología (CONACYT), Academia Nacional de Medicina. México; 2015. Available from: <http://www.anmm.org.mx/publicaciones/CANivANM150/L15-Acciones-para-enfrentar-a-la-diabetes.pdf>
4. Tarr JM, Kaul K, Chopra M, Kohner EM, Chibber R. Pathophysiology of diabetic retinopathy. *ISRN Ophthalmol.* 2013;343560. doi: 10.1155/2013/343560.
5. Early Treatment Diabetic Retinopathy Research Group. Grading diabetic retinopathy from stereoscopic color fundus photographs-An extension of the modified Airlie House Classification: ETDRS report number 10. *Ophthalmology.* 1991;98(5) Suppl: 786-806.
6. Wilkinson CP, Ferris FL III, Klein RE, Lee PP, Agardh CD, Davis M, et al. Proposed international clinical diabetic retinopathy and diabetic macular edema disease severity scales. *Ophthalmology.* 2003;110(9):1677-82.
7. Waugh N. Should automated grading of retinal photographs be used in Scottish Diabetic Retinopathy Screening Service? 2009. Available from: <http://www.ndrs-wp.scot.nhs.uk/wp-content/uploads/2013/04/2009-06-09-Retinal-autograd-ing-Waugh-FINAL.pdf>
8. Vallance JH, Wilson PJ, Leese GP, McAlpine R, MacEwen CJ, Ellis JD. Diabetic retinopathy: More patients, less laser: A longitudinal population-based study in Tayside, Scotland. *Diabetes Care.* 2008;31(6): 1126-31.
9. Asociación para la Defensa de la Discapacidad Visual, la Baja Visión y la Ceguera Legal. Escala de Wecker [Internet]. Available from: <https://asociaciondoce.com/escala-de-wecker/>
10. Yau JW, Rogers SL, Kawasaki R, Lamoureux EL, Kowalski JW, Bek T, et al. Global prevalence and major risk factors of diabetic retinopathy. *Diabetes Care.* 2012;35(3):556-64.
11. Diabetes Control and Complications Trial/Epidemiology of Diabetes Interventions and Complications (DCCT/EDIC) Research Group. Modern-day Clinical course of type 1 Diabetes mellitus after 30 years' duration: The diabetes control and complications trial/epidemiology of diabetes interventions and complications and Pittsburgh epidemiology of diabetes complications experience (1983-2005). *Arch Intern Med.* 2009;169(14):1307-16.
12. Carrillo-Alarcón LC. et al, Prevalencia de retinopatía diabética en pacientes con diabetes mellitus tipo 2 en Hidalgo, México. *Rev Mex Oftalmol.* 2011;85(3): 142-7.
13. Rodríguez-Villalobos E, Cervantes-Aguayo F, Vargas-Salado E, Ávalos-Muñoz ME. Retinopatía diabética: incidencia y progresión a 12 años. *Cir Ciruj.* 2005;73:79-84.
14. Quiroz Mercado H, Melo Granados EA, Morales Cantón V, Garza Karren C, Guerrero Naranjo JL, Bajoras Weber E. Prevalencia y gravedad de retinopatía diabética en una población del Estado Durango. *Rev Mex Oftalmol.* 2000;74(6):263-6.
15. Prado-Serrano A, Guido-Jiménez MA, Camas-Benítez JT. Prevalencia de retinopatía diabética en población mexicana. *Rev Mex Oftalmol.* 2009;83(5):261-6.
16. Vetrini D, Kiire CA, Burgess PI, Harding SP, Kayange PC, Kalua K, et al. Incremental cost-effectiveness of screening and laser treatment for diabetic retinopathy and macular edema in Malawi. *PLoS One.* 2018 Jan 4;13(1):e0190742.
17. Sender Palacios MJ, Maseras Boverb M, Vernet Vernet M, Larrosa Sáeza P, Puente Martorell ML, Foz

- Salad M. Aplicación de un método de detección precoz de retinopatía diabética en la Atención Primaria de Salud. *Rev Clín Esp.* 2003;203(5):224-9.
18. Smith-Morris C, Bresnick GH, Cuadros J, Bouskill KE, Pedersen ER. Diabetic retinopathy and the cascade into vision loss. *Med Anthropol.* 2018 jan 17:1-14.
 19. Lee R, Wong TY, Sabanayagam C. Epidemiology of diabetic retinopathy, diabetic macular edema and related vision loss. *Eye Vis.* 2015;2:17.
 20. Kempen GI, Balleman J, Ranchor AV, van Rens GH, Zijlstra GA. The impact of low vision on activities of daily living, symptoms of depression, feelings of anxiety and social support in community-living older adults seeking vision rehabilitation services. *Qual Life Res.* 2012;21(8):1405-11.
 21. Van Katwyk S, Jin YP, Trope GE, Buys Y, Masucci L, Wedge R, et al. Cost-utility analysis of extending public health insurance coverage to include diabetic retinopathy screening by optometrists. *Value Health.* 2017 sep;20(8):1034-40.
 22. Sundling V, Gulbrandsen P, Straand J. Sensitivity and specificity of Norwegian optometrists' evaluation of diabetic retinopathy in single-field retinal images-A cross-sectional experimental study. *BMC Health Serv Res.* 2013 jan 10;13:17.

