

January 2018

Estudio del espesor corneal central mediante técnicas de no contacto: microscopio especular (Nidex CEM-530), tomógrafo corneal (Pentacam HR) y tomógrafo de coherencia óptica (Cirrus HD-OCT 5000) en pacientes adultos sanos

Patricia González-Rodríguez

Clínica Rementería, pgonzalez@clinicarenteria.es

Vanesa Blázquez-Sánchez

Clínica Rementería, pgonzalez@climicarenteria.es

Sara Fernández-Cuenca

Clínica Rementería, pgonzalez@climicarenteria.es

Follow this and additional works at: <https://ciencia.lasalle.edu.co/svo>



Part of the [Eye Diseases Commons](#), [Optometry Commons](#), [Other Analytical, Diagnostic and Therapeutic Techniques and Equipment Commons](#), and the [Vision Science Commons](#)

Citación recomendada

González-Rodríguez P, Blázquez-Sánchez V y Fernández-Cuenca S. Estudio del espesor corneal central mediante técnicas de no contacto: microscopio especular (Nidex CEM-530), tomógrafo corneal (Pentacam HR) y tomógrafo de coherencia óptica (Cirrus HD-OCT 5000) en pacientes adultos sanos. *Cienc Tecnol Salud Vis Ocul*. 2018;(1): 25-31. doi: <https://doi.org/10.19052/sv.4365>

This Artículo de Investigación is brought to you for free and open access by the Revistas científicas at Ciencia Unisalle. It has been accepted for inclusion in *Ciencia y Tecnología para la Salud Visual y Ocular* by an authorized editor of Ciencia Unisalle. For more information, please contact ciencia@lasalle.edu.co.

Study of central corneal thickness using non-contact techniques: Specular microscopy (Nidek CEM-530), corneal tomography (Pentacam HR), and optical coherence tomography (Cirrus HD-OCT 5000) in healthy adult patients

Estudio del espesor corneal central mediante técnicas de no contacto: microscopio especular (Nidex CEM-530), tomógrafo corneal (Pentacam HR) y tomógrafo de coherencia óptica (Cirrus HD-OCT 5000) en pacientes adultos sanos

PATRICIA GONZÁLEZ-RODRÍGUEZ* ✉
VANESA BLÁZQUEZ-SÁNCHEZ**
SARA FERNÁNDEZ-CUENCA***

Received: 07-22-2017 / Accepted: 11-03-2017

ABSTRACT

Objective: To study and compare the value of central corneal thickness in a healthy adult population, using different non-contact techniques from daily clinical practice. **Method:** This work examines and compares the pachymetric measurements of 71 eyes of 36 healthy adult patients. Corneal thickness was evaluated using three non-contact instruments: a CEM-530 specular microscope (Nidek), Pentacam HR corneal tomography (Oculus), and Cirrus HD-OCT 5000 optical coherence tomography (Carl Zeiss Meditec). Tests were performed consecutively by a single observer in the same session and under the same environmental conditions. **Results:** The results obtained using the three devices are interchangeable, given that no statistically significant difference was observed among them. The study did not find statistically significant difference with respect to gender either. **Conclusion:** These three non-contact methods for the measurement of corneal central pachymetry are a reliable alternative to ultrasonic contact pachymetry.

Keywords: central corneal thickness, pachymetry, non-contact instruments, cornea.

* BA in Optics and Optometry. Clínica Rementería, Madrid, Spain. ✉ pgonzalez@climicarenteria.es

** PhD in Optics and Optometry. Clínica Rementería, Madrid, Spain.

*** MA in Optometry and Vision. Clínica Rementería, Madrid, Spain.

How to cite this article: González-Rodríguez P, Blázquez-Sánchez V, Fernández-Cuenca S. Study of central corneal thickness using non-contact techniques: Specular microscopy (Nidek CEM-530), corneal tomography (Pentacam HR), and optical coherence tomography (Cirrus HD-OCT 5000) in healthy adult patients. *Cienc Tecnol Salud Vis Ocul*. 2018;16(1):25-31. doi: <https://doi.org/10.19052/sv.4365>

RESUMEN

Objetivo: estudiar y comparar el valor del espesor corneal central en una población adulta sana, mediante diferentes técnicas de no contacto utilizadas en la práctica clínica diaria. **Método:** en este trabajo se estudian y comparan las medidas paquimétricas de 71 ojos de 36 pacientes adultos sanos. La valoración del espesor corneal se realizó mediante tres instrumentos de no contacto: el microscopio especular CEM-530 (Nidek), el tomógrafo corneal Pentacam HR (Oculus) y la tomografía de coherencia óptica Cirrus HD-OCT 5000 (Carl Zeiss Meditec). Las pruebas se realizaron consecutivamente por un solo observador en una misma sesión y en las mismas condiciones ambientales. **Resultados:** los resultados obtenidos son intercambiables entre los tres aparatos utilizados, no observándose diferencias estadísticamente significativas entre ellos. Tampoco se encontraron diferencias estadísticamente significativas respecto al género. **Conclusión:** estos tres métodos de no contacto corneal para la medida de la paquimetría central suponen una alternativa fiable a la paquimetría ultrasónica de contacto.

Palabras clave: espesor corneal central, paquimetría, instrumentos de no contacto, córnea.

INTRODUCTION

The cornea is the most anterior layer of the eye; it is a clear, avascular structure innervated by branches of the trigeminal nerve. The nerves enter the cornea through the stroma and cross Bowman's membrane in order to reach the epithelium. The normal central corneal thickness in an adult eye ranges between 540 and 560 microns (μm), increasing to values between 660 and 700 μm near the limbus. These normal values may vary greatly both during the day and the subject's lifetime (1).

The accurate measurement of central corneal thickness is important since it is an essential part of the evaluation of candidates for refractive or cataract surgery, as well as in patients with glaucoma or corneal diseases. In refractive surgery, knowing the central corneal thickness and determining if the cornea is sufficient to undergo the necessary ablation is a prerequisite for planning a successful intervention.

During the preoperative evaluation of candidates for cataract surgery, the evaluation of central corneal thickness is very useful, particularly in patients with corneal guttae, which may signal the presence of Fuchs' dystrophy (2). It helps the ophthalmologist to plan the surgical parameters in order to minimize corneal damage and achieve a better visual improvement. It may also help guide

the decision of which intraocular lens should be chosen.

During routine revisions, central corneal thickness may help diagnose corneal diseases; it is used both for diagnosis and follow-up of several ectasias and corneal diseases (3).

Central corneal thickness is also a vital parameter in eyes with glaucoma, since it is necessary to adjust intraocular pressure measurements (4).

Due to the importance of central corneal thickness and to several technological developments, pachymetry can now be performed with different techniques, such as ultrasonic pachymetry, optic pachymetry, interferometry, specular pachymetry, anterior chamber optical coherence tomography (OCT) and other experimental techniques (5).

Ultrasonic pachymetry is still considered the gold standard, although it has several limitations. Since it is a contact technique, it requires the instillation of topical anesthesia, which may be uncomfortable for the patient and produce corneal toxicity. The probe may damage the corneal epithelium. Furthermore, the value obtained may depend on the experience of the operator, due to the force that needs to be applied with the probe and its alignment with the visual axis. However, it is easy to use, and most devices are simple, portable and

relatively inexpensive, therefore remaining as the gold standard. Non-contact methods have been developed to try to overcome the disadvantages of ultrasonic pachymetry (6).

The purpose of this study was to compare three current, contactless techniques to evaluate their fiability in a clinical practice setting.

MATERIALS AND METHODS

A prospective observational study was performed to compare different contactless pachymetry techniques. Subjects with no known ophthalmic disease who attended Clínica Rementería in Madrid, Spain, during the month of March, 2017 for a routine check-up were considered for inclusion. Subjects willing to participate were included. All measurements were performed by a single operator, in a single, morning session in order to avoid interobserver variations (7), as well as variations in corneal thickness due to personal or environmental factors.

Seventy one eyes of 36 healthy, Caucasian adults were examined; there were 10 men (23%) and 26 women (73%) with a mean age of 70.81 ± 5.21 years.

Corneal thickness values were obtained with specular microscopy (Nidek CEM-530), Pentacam HR (Oculus Scheimpflug corneal topography) and optical coherence tomography (Cirrus HD-OCT 5000).

The first measurement was performed with the Nidek CEM-530 specular microscope (Figure 1), which aligns itself with the eye, focuses and captures an image automatically. Eight images are taken in each capture; the one with the best quality was selected. It is a device that captures images and provides a quick and easy analysis. The image of the cornea it provides is obtained by measuring the reflection of the anterior and posterior cornea. The distance between both re-

fections, which is calculated automatically, is the central pachymetry. It also provides an image of the endothelium, allowing an easy follow-up of the size and shape of the cells (Figure 2).



FIGURE 1. Nidek CEM-530 specular microscope



FIGURE 2. Image of the endothelium obtained with specular microscopy

Measurements were performed in scotopic conditions with the patient resting chin and forehead on the device. The subject was asked not to blink during image acquisition and to keep looking at the central fixation spot. A single capture of the central cornea of 0.25×0.55 mm was acquired.

Optical coherence tomography was performed next, with the anterior segment module, of the Cirrus HD-OCT 5000 (Carl Zeiss Meditec). This device can measure corneal thickness using infrared interferometry (Figure 3) at whichever point is being scanned. For this study, the central cornea was selected. Thanks to the real time visualization during scanning, the operator can control the exact

point he wants to measure. Once the image was acquired, the Caliper tool was used to manually mark two perpendicular points; the device then provided the corneal thickness between those two points (Figure 4).

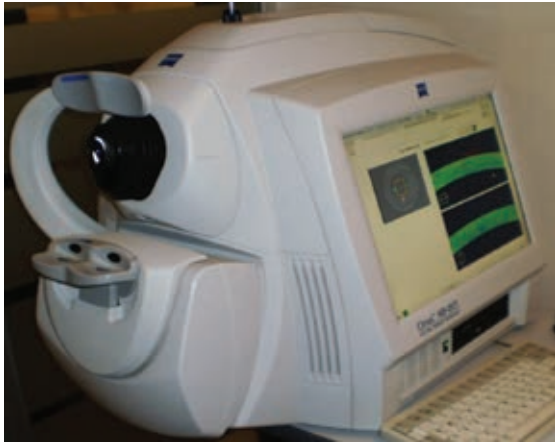


FIGURE 3. Cirrus HD-OCT 5000 (Carl Zeiss Meditec)

Optical coherence tomography was also performed in scotopic conditions, with the subject resting chin and forehead on the device. The subject was asked to look at the fixation light in the middle of the camera. A scan was considered valid if signal strength was good (six or more points in a 10-point scale). The device uses a superluminescent diode light source and performs 4000 scans per second, analyzing a 6 mm square area in the center of the cornea, which is divided in eight sectors. It then calculates the remaining points by interpolation (8).

Corneal topography with Pentacam HR was performed next; it has a system of rotating Scheimpflug cameras, which provides simultaneous data on topography, corneal elevation and pachymetry at different points of the cornea (Figure 5). The system uses three different rotating cameras and a blue light source with a 475 μm wave-length, which rotate together around the optic axis, acquiring a three-dimensional image. In two seconds, the device obtains 25 images encompassing 500 measurement points of the anterior and posterior corneal surface, which amounts to 25.000 elevation points for each surface and creates a corneal elevation map (Figure 6) (9).



FIGURE 5. Pentacam HR




FIGURE 4. Pachymetry performed with optical coherence tomography

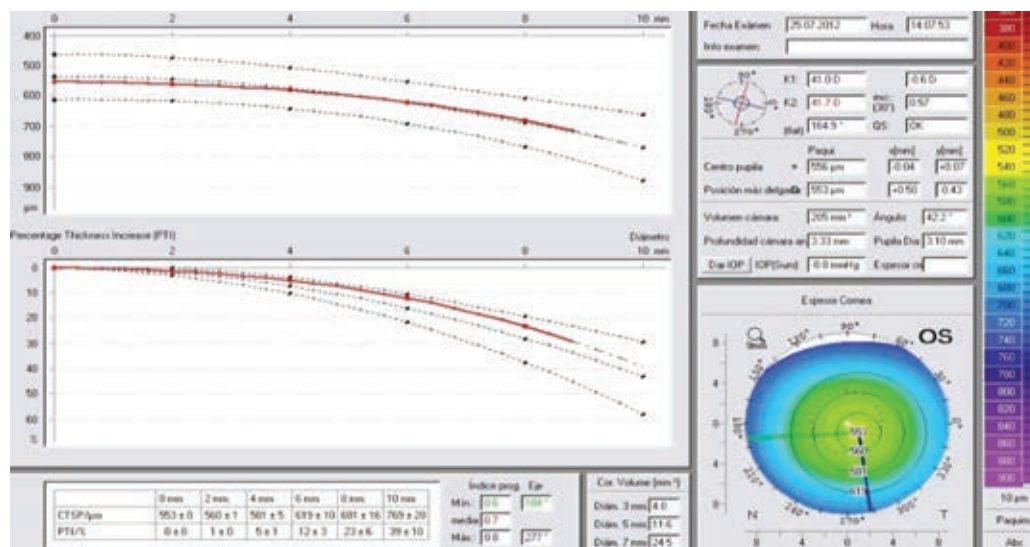


FIGURE 6. Pachymetry map obtained with the Pentacam corneal topography

For tomography, three measurements were acquired and a mean was calculated. The exam was performed with the automatic mode until it was considered valid in scotopic conditions and with the patients resting chin and forehead on the device. Subjects were asked to avoid blinking and to keep their gaze on the central fixation spot.

All procedures were performed according to the Principles of the Declaration of Helsinki. The right eye was always examined first. Statistical analysis was performed with SPSS software.

RESULTS

A total of 71 eyes were included in the study (36 right eyes and 35 left eyes). The measurements obtained with each device are provided in Table 1.

TABLE 1. Corneal pachymetry values obtained with each device

DEVICE	RIGHT EYE	LEFT EYE
Specular microscope CEM-530	549.9 ± 32.7 µm	554.9 ± 32.5 µm
Cirrus HD-OCT 5000	538.4 ± 31.7 µm	542.5 ± 31.9 µm
Pentacam HR	544.2 ± 30.4 µm	550.1 ± 32.7 µm

Statistical analysis was performed with the SPSS software. The mean and standard deviation for each device was calculated, as well as the intraclass correlation coefficient (ICC). Bland-Altman graphics were also plotted.

The values obtained with the Pentacam HR corneal topography and the CEM-530 specular microscope were very similar, while those obtained with the anterior module of the Cirrus HD-OCT 5000 were lower, although the difference was not statistically significant ($p < 0.05$). ICC showed there was a good correlation for both eyes. The values obtained are shown in Table 2.

TABLE 2. Intraclass correlation coefficient for each eye between the different devices analyzed

RIGHT EYE	PENTACAM HR	CEM-530	HD-OCT 5000
Pentacam HR		0.973	0.994
CEM-530	0.973		0.989
HD-OCT 5000	0.994	0.989	

LEFT EYE	PENTACAM HR	CEM-530	HD-OCT 5000
Pentacam HR		0.951	0.972
CEM-530	0.951		0.954
HD-OCT 5000	0.972	0.954	

Regarding the relationship between the measurements obtained and the eye examined, left eye values were slightly higher than right eye values. There were no significant differences according to gender ($p < 0.05$).

DISCUSSION

This study compares central corneal pachymetry values obtained with several non-invasive devices. There are multiple previous publications that analyse the correlation between different devices (10-14).

The gender distribution in this study was not balanced, since, according to Weiser et al. (15), central corneal thickness measurements are not influenced by age, race or gender. We did find a statistically significant difference between right and left eye values, which may be due to a more favorable position of the operator.

Hekimoglu et al. (16) found that thickness measurements were affected by factors such as localization and direction, previous pupillary dilatation, and involuntary movements. In order to eliminate these factors, we did not perform ultrasonic pachymetry and chose to compare contactless devices which are can detect almost automatically the corneal center, therefore providing a better precision and repeatability for each measurement.

Several reports have found that HD-OCT provides corneal measurements that are lower than those obtained with contact methods (17-19). They suggest that topical anesthesia may produce mild corneal edema. Furthermore, the algorithms employed by different devices for corneal thickness calculation may provide slightly different pachymetric values. Other authors have found that measurements obtained with Cirrus HD-OCT are greater than those provided by contact ultrasonic pachymetry (11,20).

Weiser et al. (15) and Calvo et al. (10) have reported that OCT and contact ultrasonic pachymetry provide similar values. On the other hand, and in contrast with our results, De Bernardo (13) and Fujioka (14) found slightly lower pachymetric values with the specular microscope compared to the Pentacam topography.

In spite of the different protocols followed in each study (10,13,14), most have found a high resolution between the analyzed devices, as in the present study. This high correlation between devices was also reported by other authors, such as Cevik et al. (11), who compared ultrasonic pachymetry and specular biomicroscopy.

Several authors consider that OCT slightly overestimates pachymetric values, but that it has advantages such as its fiability, the ease with which it is performed and the fact that it is a contactless technique and therefore safer than ultrasonic pachymetry (20). These characteristics are shared with the other devices used in this study.

Bourges (21) reported that the current contactless techniques for measuring corneal thickness are lowly reproducible, with a high intervariability between them, and therefore suggests that they may replace ultrasonic pachymetry as the gold standard.

CONCLUSIONS

Corneal thickness measurement is currently a fundamental part of ophthalmologic examinations, providing valuable information for the diagnosis, follow-up and treatment of multiple diseases.

Due to its relevance, new quantitative and qualitative techniques have been developed for corneal thickness measurement. This study has analyzed three different devices that quantitatively evaluate the cornea without direct contact with the corneal

surface and which are already part of current ophthalmological practice.

In clinical practice, the Cirrus HD-OCT 5000 is already considered a reliable alternative to ultrasonic pachymetry. Our study also shows that Pentacam HR and the CEM-530 specular microscopy may also be valid alternatives.

CONFLICT OF INTEREST

The authors declare to have no conflict of interest.

REFERENCES

- Fernández Cuenca S, Blázquez Sánchez V, Hurtado FJ. Estudio comparativo de medidas de espesor corneal mediante paquimetría ultrasónica, topógrafo corneal (Oculus) y tomografía de coherencia óptica (OCT) de polo anterior. *Gaceta Óptica*. 2014;(491):24-8.
- Miranda Hernández I, Fernández García K, Ruiz Rodríguez Y, Hernández Silva JR, Rio Torres M. Comparación de los valores del espesor corneal central según los equipos Lenstar, Galilei y Pentacam. *Rev Cubana Oftalmol*. 2012;25(1):65-71.
- Gros-Otero J, Arruabarrena-Sánchez C, Teus M. Espesor corneal central en una población sana española. *Arch Soc Esp Oftalmol*. 2011;86(3):73-6.
- Brandt JD, Beiser JA, Kass MA, Gordon MO. Central corneal thickness in the Ocular Hypertension Treatment Study (OHTS). *Ophthalmology*. 2001;108(10):1779-88.
- Federico V, Pravato ML, Cremonini P, Chialvo A. Comparación del espesor corneal central: Orbscan II versus paquimetría ultrasónica. *Oftalmol Clin*. 2009;3(2):46-52.
- López de la Rosa A. Actualización en técnicas de paquimetría [thesis]. [Valladolid]: Universidad de Valladolid; 2014.
- Liu Z, Pugheider SC. Corneal thickness is reduced in dry eye. *Cornea*. 1999;18:403-7.
- Carl Zeiss Meditec [Internet]. Cirrus HD-OCT 5000 User Manual. Available from: <https://www.zeiss.com/meditec/int/products/ophthalmology-optometry/glaucoma/diagnostics/oct/oct-optical-coherence-tomography/cirrus-hd-oct.html>
- Blanco García O, Blanco García N, Guerrero Vargas J. Topografía Pentacam Oculus [Internet]. Available from: https://issuu.com/centinel/docs/manual_pentacam_oculus
- Calvo Sanz JA, Ruiz-Alcocer J, Sánchez-Tena MA. Accuracy of Cirrus HD-OCT and Topcon SP-3000P for measuring central corneal thickness. *J Optom*. 2017. doi: <http://dx.doi.org/10.1016/j.optom.2016.12.004>
- Ayala M, Standas R. Accuracy of optical coherence tomography (OCT) in pachymetry for glaucoma patients. *BMC Ophthalmol*. 2015;15:124.
- Cevik SD, Rahmi R, Cevik MT, Kivanc SA. Comparison of central thickness estimates by an ultrasonic pachymeter and non-contact specular microscopy. *Arq Bras Oftalmol*. 2016;79(5):312-4.
- De Bernardo M, Borrelli M, Mariniello M, Lanza M, Rosa N. Pentacamvs SP3000P specular microscopy in measuring central corneal thickness. *Cont Lens Anterior Eye*. 2015;38(1):21-7.
- Fujioka M, Nakamura M, Tatsumi Y, Kusuhara A, Maeda H, Negi A. Comparison of Pentacam Scheimpflug camera with ultrasound pachymetry and noncontact specular microscopy in measuring central corneal thickness. *Curr Eye Res*. 2007;32(2):89-94.
- Weise K, Kaminski B, Melia M, Repka M, Bradfield Y, Davitt B, et al. Intraobserver reliability of contact pachymetry in children. *J AAPOS*. 2013 apr;17(2):144-48.
- Hekimoglu E, Kazim Enol M, Toslak D, Turgut D, Doğan B, Yucel O. Comparison of measurement of central corneal thickness with spectral domain optical coherence tomography and standard ultrasonic pachymeter in premature infants. *J Ophthalmol [Internet]*. 2015. Available from: <https://www.ncbi.nlm.nih.gov/pmc/articles/PMC4525755/>
- Zhao PS, Wong TY, Wong WL, Saw AM, Aung T. Comparison of central corneal thickness measurement by visante anterior segment optical coherence tomography with ultrasound pachymetry. *Am J Ophthalmol*. 2007;147(6):1047-50.
- Kim HY, Budenz DL, Lee PS, Feuer WJ, Barton K. Comparison of central corneal thickness using anterior segment optical coherence tomography ultrasound pachymetry. *Am J Ophthalmol*. 2008;145(2):228-32.
- Li EY, Mohamed S, Leung CK, Rao SK, Cheng AC, Cheung CY, Lam DS. Agreement among 3 methods to measure corneal thickness: ultrasound pachymetry, Orbscan II and Visante anterior segment optical coherence tomography. *Ophthalmology*. 2007;114(10):1842-47.
- Leung DY, Lam DK, Yeung BY, Lam DS. Comparison between central corneal thickness measurements by ultrasound pachymeter and optical coherence tomography. *Clin Exp Ophthalmol*. 2006;34(8):751-4.
- Bourges JL, Alfonsi N, Laliberté JF, Chagnon M, Renard G, Legeais JM, et al. Average 3-dimensional models for the comparison of Orbscan II and Pentacam pachymetry maps in normal corneas. *Arq Bras Ophthalmol*. 2009;116(11):312-4.